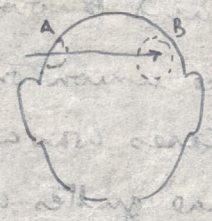


This is only a preliminary report but I believe I can send you a later report of their progress.

Sincerely  
Harold E. Jones

PS In the trans cerebral cases



When you do the debridement at A, we wonder whether a debridement should be done at B.

Dr. Cone ✓  
Dr. Elliott

31 August 42  
#1 Neurosurgical  
Hospital

Dear Doctor Penfield,

I thought you might like to know about the first actual war casualties of a neurosurgical nature; Brigadier Currie was to see the series as it has been his first opportunity to see anything like that approaching Cushing's experiences. There were 6 GSW heads all told and 1 GSW spine - this seems to be a very small number but it is presumed that the other 296 were left behind - I say 296 since Peter Ashcroft in Libya

temporal soft tissues. In all  
whenever ~~the~~ missile penetrated  
there was a great deal of chattering  
of the skull with undrawn bony  
fragments. All of the cases had  
several other wounds requiring  
"several operations."

In the cerebral penetration cases  
complete debridement was done  
including the dura and we  
wonder now whether we should  
inject oxygen subdurally  
after your method to separate  
the brain and attempt to  
minimize venous cerebral  
occlusion. No attempt was  
made to close the dural defect.

They have all done fairly well.

Les had at <sup>least</sup> 750 GSW heads now  
and says that neurosurgeons were  
cautious about it as in the case  
was to about 20%. In every  
case the wounds were 36 to 48 hours  
old. There were 2 trans cerebral  
from one <sup>side of</sup> occiput to the other both of  
whom showed some vesical excretion.  
The first one which ~~was~~ was in  
The wound of entry in every case was  
healed and all the wounds healed  
by primary union and photographs  
were obtained with nice union on the  
5th day. One of the cases was a through  
and through unilateral gutter wound  
with the large groove through the left  
side of his brain. Another case was  
a 5 cm penetration into occipital  
lobe. Another case was a scalp  
laceration with considerable temporal  
contusion and the final one had  
considerable damage to the right